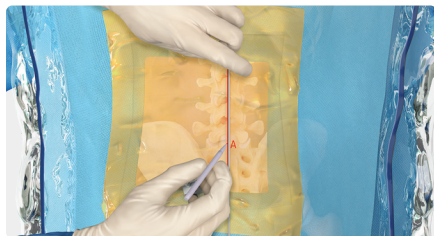


Transforaminal Approach for Discectomy

Quick Reference Guide

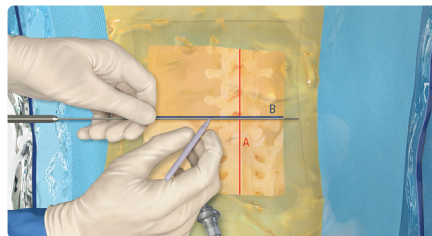
View full surgical
technique



A

Midline

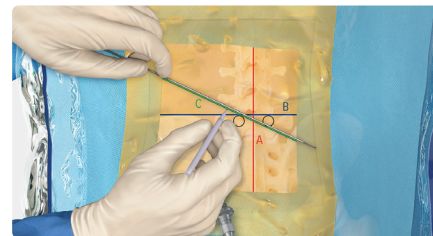
- With a blunt dissector, mark the midline using the spinous processes as reference (Line A).



B

Disc Space

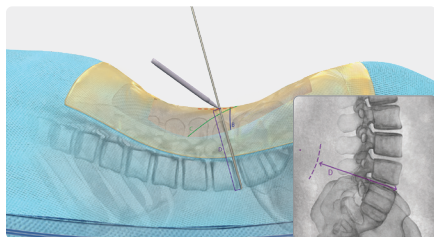
- Mark the disc space at the level of herniation (Line B).



C

Oblique Line

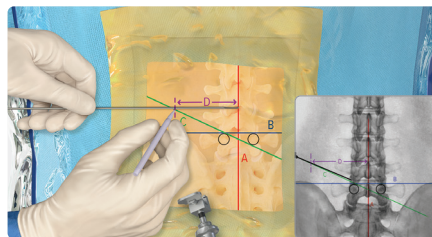
- Mark the oblique line from the superior ipsilateral pedicle to the inferior contralateral pedicle (Line C).



D

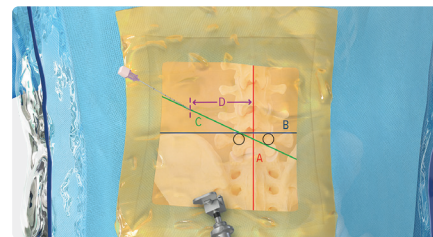
Measuring Lateral Line

- On lateral x-ray, measure the distance from the ventral disc space to the surface of skin (Line D).



Marking Lateral Line

- From the midline (Line A), mark a horizontal line that is the length of Line D to intersect the oblique line (Line C). This is your starting point for needle placement.



Needle Placement