

ISSUE 04

# ShARC BITE

**CORRECTIVE REAMING IN ANATOMIC TSA**

RELEASED JANUARY 2025



---

## Mission Statement

The Shoulder Arthroplasty Research Committee (ShARC) is a forward-looking global collaboration among research-focused surgeons of which the primary goal is to advance patient care. The ShARC Patient Registry is utilized to conduct patient monitoring, inform evidence-based implant design, and allow for the integration of novel technologies into clinical practice. Supported by Arthrex, the ShARC will continue to have tremendous influence on the advancement of shoulder arthroplasty through innovative research and a commitment to improve patient outcomes.

**ShARC Bites** are developed through registry data analysis and processing of the committee's preferences, cross-referenced with available ShARC and non-ShARC publications, to provide recommendations on current techniques and implants.

---

## Summary Recommendation

In anatomic total shoulder arthroplasty, the majority of ShARC surgeons will use a standard glenoid component and perform corrective reaming of a B2 glenoid in cases with preoperative retroversion of 15° or less and an augmented glenoid component in cases with 15° to 25° of retroversion. Further, the vast majority of ShARC surgeons limit their corrective reaming to <3 mm in an effort to preserve subchondral bone. Finally, the majority of ShARC surgeons feel that the upper limit for utilizing an augmented anatomic glenoid component is 25° of glenoid retroversion.

### Construct Comparison



**Glenoid Reamer**

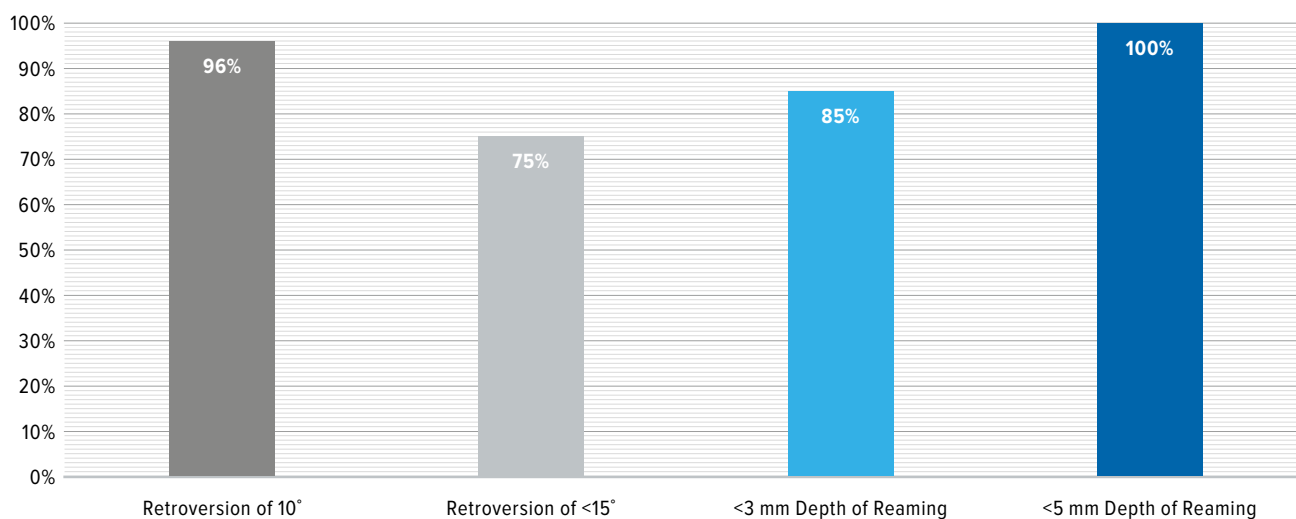
## Background

Management of glenoid deformity in anatomic total shoulder arthroplasty is accomplished through a variety of options based on severity of deformity, patient age and activity level, as well as surgeon preference and experience. The Walch classification delineates the common glenoid pathologic deformities and recognizes that the B2 or “biconcave” glenoid is a common deformity observed in primary glenohumeral arthritis.<sup>1</sup> Historically, especially prior to the availability of augmented polyethylene anatomic glenoid components, the B2 glenoid was managed with corrective or “high-side” reaming in an effort to correct pathologic glenoid retroversion to a more anatomic version and improve backside seating of the glenoid component. Classic limitations to corrective reaming have been delineated by Iannotti and others and include reaming <3-4 mm to preserve glenoid subchondral bone and correcting <15° of deformity.<sup>2</sup> Recently, a series published by Harold et al found that at a mean of 8 years follow-up, 88% of glenoid components in 34 shoulders remained well fixed radiographically following corrective reaming of glenoids, with an average preoperative retroversion of 19°.<sup>3</sup>

### Corrective Reaming ShARC Surgeon Preference Survey Results

When managing a B2 glenoid in anatomic total shoulder arthroplasty, 96% of ShARC surgeons will perform a corrective reaming technique for preoperative glenoid retroversion of 10° and 75% will perform corrective reaming in cases with up to 15° of glenoid retroversion. When assessing depth of corrective reaming, 85% of ShARC surgeons limit the depth to <3 mm and 100% limit it at <5 mm.

#### Corrective Reaming of B2 Glenoid in Anatomic Total Shoulder Arthroplasty



In cases where glenoid retroversion increases to 20°, 96% of ShARC surgeons prefer to use an augmented polyethylene anatomic glenoid component. However, if glenoid retroversion is >25°, 93% of ShARC surgeons state that the severity of retroversion is too much to be optimally managed with an augmented polyethylene glenoid component and would consider performing a reverse total shoulder arthroplasty.

## References

---

1. Walch G, Badet R, Boulahia A, Khoury A. Morphologic study of the glenoid in primary glenohumeral arthritis. *J Arthroplasty*. 1999;14:756-760. doi:10.1016/s0883-5403(99)90232-2
2. Ho JC, Savesan VJ, Iannotti JP. Glenoid component retroversion is associated with osteolysis. *J Bone Joint Surg Am*. 2013;95:e82. doi:10.2106/JBJS.L.00336
3. Harold RE, Sweeney PT, Torchia MT, Chamberlain AM, Keener JD. Total shoulder arthroplasty in patients with a B2 glenoid addressed with corrective reaming: mean of 8-year follow up. *J Shoulder Elbow Surg*. 2023;32:S8-S16. doi:10.1016/j.jse.2022.12.019



View the ShARC  
Publication List

**ShARC**  
Shoulder Arthroplasty Research Committee

